

Perforating Internal Root Resorption Repaired with Mineral Trioxide Aggregate Caused Complete Resolution of Odontogenic Sinus Mucositis: A Case Report.

Bendyk-Szeffer M¹, Łagocka R², Trusewicz M², Lipski M³, Buczkowska-Radlińska J².

¹Department of Conservative Dentistry with Endodontics, Pomeranian Medical University, Szczecin, Poland.; ²Department of Conservative Dentistry with Endodontics, Pomeranian Medical University, Szczecin, Poland ; ³Department of Preclinical Conservative Dentistry and Preclinical Endodontics, Pomeranian Medical University, Szczecin, Poland

BACKGROUND /CONTEXT: Here is an example plan for the clinical session. You can change it according your work but abstracts **must** adhere to the following style. You can present a case report, case series or clinical techniques. The required styles illustrated in this Microsoft WORD document, must be used as a template for production of abstracts, by replacing the relevant text with your own. The easiest way to use this abstract form is by cutting and pasting of unformatted text to maintain the documents present format.

METHODS/CASE REPORT DESCRIPTION:

All abstracts must be formatted for only A4 paper (210 x 297 mm). The top margin should be set to 15 mm, bottom margin to 25 mm, and left and right margins to 20 mm. The entire document is set to 2 columns with 10 mm of intercolumn spacing (giving a column width of 80 mm). The body of the document should be set in 11 pt Times New Roman, justified, with single line-spacing. Do not use fonts other than Times New Roman (or Times), Symbol, and MTEExtra in the document (including equations and figures).

Title should be in bold all-caps.

Author should be listed consecutively (as shown above) by initials and last name. Authors may be hyperlinked to the e-mail address (as shown above).

Affiliation should be indicated with superscripted suffix Arabic numerals. Do not append degrees, professional designations, etc., to names. Affiliations should be listed consecutively and may be hyperlinked to the related web page (as shown above).

RESULTS / MONITORING: Sample reference entries [1-4] are given in the References section. References should be set as one block, as below, and a maximum of four references may be used. Figures should use *Figure* style and have the caption below them. Tables should use *Table* style and have the caption above them. Figure and table caption styles are *Fig Caption* and *Table Caption*, respectively. Scanned figures should have a minimum resolution of 300 dpi for an 80 mm figure width. EPS or TIFF is the preferred format.

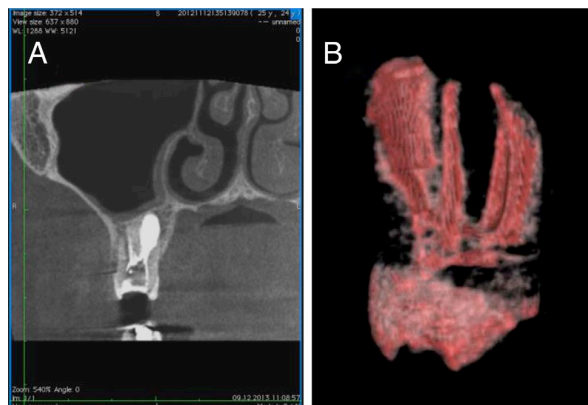


Fig. (A) A CBCT scan (coronal section) at the level of the first molar 6 months after completion of root canal treatment. A soft tissue density mass superior to tooth 16 had completely resolved. (B) Three dimensional visualization of internal anatomy of tooth 16 after root canal obturation ⁴

DISCUSSION & CONCLUSIONS: Abstracts must not exceed one page. Please submit the abstract as a Word 97/2000/XP/2003 document for Windows, or Word 98/2001/X/2004 document for Mac. Only electronic submissions will be accepted.

ENDODONTIC OR CONSERVATIVE DENTISTRY RELEVANCE: Please provide a brief statement that succinctly summarizes the endodontic or conservative dentistry interest of the findings described in your manuscript.

REFERENCES: ¹ M. Ziegler (1991) *Essentials of Writing Biomedical Research Papers*, McGraw-Hill, Inc. ² I.R. Spears, M. Pfliegerer, E. Schneider, et al (2000) *J Biomech* **33**:1471-77. ³ A.R Poole, M. Alini, and A Hollander (1995) Chondrocytes and cartilage destruction in *Mechanisms and Models in Rheumatoid Arthritis* (eds B. Henderson, J. Edwards, and R. Pettipher) Academic Press, pp 163-204. ⁴ M Bendyk-Szeffer et al (2015) *J Endod* **41**:274-8

ACKNOWLEDGEMENTS: This template was initially modified with kind permission from European cells and Materials Journal. This case report is in section References (4).